

Skin Health



FROM THE KIMBERLY AND ERIC J. WALDMAN DEPARTMENT OF DERMATOLOGY

SPRING/SUMMER 2019

IN THIS ISSUE

2
Mount Sinai Launches a Dermatology Practice in the Heart of the Upper West Side

3
Orentreich Professorship Honors a Great Legacy

4/5
Thank You to Our Supporters in 2018

6
Say Goodbye to Under-Eye Circles

World-Renowned Genetics Researcher is the First Orentreich Professor

By **Jonathan P. Ungar, MD**, Director of Consultative Dermatology, Associate Director of the Residency Program, Kimberly and Eric J. Waldman Department of Dermatology

When it comes to developing breakthrough treatments for complex skin diseases in the 21st century, understanding the role of genetics and genomics is an important first step. **Anne Bowcock, PhD**, is doing just that as the inaugural Norman Orentreich, MD, Professor of Dermatology Research in the Kimberly and Eric J. Waldman Department of Dermatology at the Icahn School of Medicine at Mount Sinai.

Some of Dr. Bowcock's most significant work resulted in the discovery of the first genetic mutation found in the type of psoriasis that runs in families.

continued on page 3



Anne Bowcock, PhD

New HPV Vaccine Guidelines for Ages 9 to 45

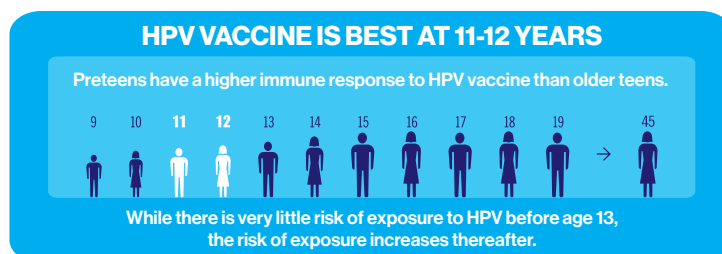
By **Mohammad-Ali Yazdani, MD**, Resident Physician, Icahn School of Medicine at Mount Sinai

About 80 percent of the population will become infected with the virus that causes warts, known as human papillomavirus (HPV), according to the Centers for Disease Control and Prevention (CDC). HPV has both low-risk and high-risk types that can infect individuals of any age or gender, although high-risk types are almost always associated with intimate contact.

Low-risk HPV types are non-cancer-causing but can produce flat warts, common warts, and plantar warts— frequently on the face, hands, elbows, knees and feet. These tend to respond to conservative therapy or go away on their own within a few years. In contrast, high-risk types of HPV are associated with persistent genital warts and cancers of the cervix, anogenital area, and throat.

High-risk HPV infection is associated with more than 40,000 new cases of cancer yearly. This is why many physicians and patients are welcoming the newly expanded guidelines for the vaccine that can prevent most cases of high-risk HPV.

continued on page 3



Mount Sinai Launches a Dermatology Practice in the Heart of the Upper West Side

By **Andrew F. Alexis, MD, MPH**, Site Chair, Kimberly and Eric J. Waldman Department of Dermatology, Mount Sinai St. Luke's and Mount Sinai West; Director, Skin of Color Center™

Searching for world-class skin care on the Upper West Side? Look no farther than our new location—Mount Sinai Doctors Ansonia.



Conveniently located at 2109 Broadway (between 73rd and 74th streets) in the historic landmark building The Ansonia, Mount Sinai Doctors Ansonia is honored to serve the community with excellent, patient-centered dermatology care from an outstanding team of physicians and support staff.

We provide a full spectrum of services: general medical dermatology, skin surgery, aesthetic procedures, and clinical research studies that offer cutting-edge therapies. Mount Sinai Doctors Ansonia is also the home of the Skin of Color Center, the first-of-its-kind facility committed to providing culturally conscious care for skin, hair, and nail problems that affect patients of color.

All of our faculty members provide general dermatology services. In addition, our dermatologists each have their own areas of expertise, such as psoriasis and skin cancer detection (**Robin Buchholz, MD**), facial rejuvenation and mole removal (**Noelani González, MD**), vitiligo, atopic dermatitis, and acne (**Nanette Silverberg, MD**), allergic contact dermatitis and hair disorders (**Meera Sivendran, MD**), and hyperpigmentation and laser hair removal (**Andrew Alexis, MD, MPH**).

Mount Sinai Doctors Ansonia offers same-day appointments, evening and weekend hours, and a secure Internet portal that allows our patients to communicate with physicians and staff.



Our dermatologists (from left): Andrew Alexis, MD, MPH, Meera Sivendran, MD, Noelani González, MD, and Nanette Silverberg, MD. Not pictured: Robin Buchholz, MD.

To make an appointment with one of our dermatologists, please call **212-523-6003** or book online at mountsinai.org/locations/msd-ansonia/dermatology/team.

The Dermatology Clinical Research Program is now enrolling patients (ages 18+) with:

- Actinic keratoses
- Alopecia areata (ages 12+)
- Eczema (ages 6+)
- Pemphigus vulgaris
- Psoriasis (all forms)
- Psoriatic arthritis
- Vitiligo (loss of pigment)

For More Information: Please contact us at **212-241-3288**.

Orentreich Professorship Honors a Great Legacy

Earlier this year, the field of dermatology lost a luminary with the passing of **Norman Orentreich, MD**. In his illustrious career, Dr. Orentreich introduced many advances—innovative theories, techniques, and inventions—that helped to define the specialty. To name a few of Dr. Orentreich’s achievements: he was the first to successfully treat male-pattern baldness with hair transplants; he founded and was first president of the American Society of Dermatologic Surgery; he was the founding director of the Orentreich Foundation for the Advancement of Science; and he was the co-creator of the Clinique® brand, the world’s first allergy tested, dermatologist-driven line of cosmetics.



Norman Orentreich, MD
1922–2019

Dr. Orentreich was also a dedicated family man. Two of his three children followed in his footsteps and became dermatologists; at Mount Sinai we are lucky to count his son **David Orentreich, MD**, as our faculty member. In 2016, the Orentreich family made a generous gift to endow the Norman Orentreich, MD, Professor of Dermatology Research—its first recipient is **Anne Bowcock, PhD** (see article on page 1)—ensuring that Dr. Orentreich’s legacy will continue to shape dermatology long into the future.

World-Renowned Genetics Researcher

continued from page 1

She also discovered two mutated genes that are key to a rare form of melanoma that develops in the eye, called uveal melanoma. “It takes time for genetic findings to impact directly on patient care, but by understanding how cancer and other diseases develop, new targeted therapies can be developed in the future,” said Dr. Bowcock.

Currently Dr. Bowcock is continuing to unravel the genetics of psoriasis and cancer. Building on the results of her research, our Department hopes to make dramatic advances in the detection and treatment of formerly intractable and lethal skin diseases.

New HPV Vaccine Guidelines for Ages 9 to 45 *continued from page 1*

The Food and Drug Administration has approved the 9-valent HPV vaccine (Gardasil®9) for children, teens, and adults from age 9 to 45. (Previously, the vaccine was FDA approved for ages 9 to 26.) The CDC recommends routine vaccination for boys and girls at age 11 or 12 in a series of two or three injections separated by several months. (More information can be found online at <https://www.cdc.gov/hpv/parents/vaccine.html>)

While there are many types of HPV, the 9-valent HPV vaccine has been shown to protect against the nine HPV types most commonly associated with sexually transmitted warts and cancer (see table). Individuals who were vaccinated with a prior Gardasil® vaccine covering fewer HPV types should consult with their doctors if they wish to receive Gardasil 9. In such cases, the new vaccine appears relatively safe and effective, but to date there is no specific recommendation.

In addition to the cancers noted above, recent studies have shown a link between HPV and squamous cell skin cancers. In the journal *JAMA Dermatology*, August 2018, Anna Nichols, MD, PhD, and colleagues at the University of Miami Health System described a case of a woman in her nineties with numerous inoperable skin cancers. After injection of HPV vaccine administered systemically and also locally into the lesions, the cancers disappeared. These results will require further study and clinical trials but raise the exciting possibility of using HPV vaccine to treat skin cancer.

The Most Common Lesions Caused by HPV and Whether Covered by 9-Valent HPV Vaccine (Gardasil 9)		
CATEGORY OF LESIONS	HPV TYPE	VACCINE COVERS?
Common warts	2, 7	No
Plantar warts	1, 2, 4	No
Flat warts	3, 10	No
Genital warts	6, 11	Yes (both types)
Persistent high-risk genital warts, pre-cancers, and cancers	16, 18, 31, 33, 45, 52, 58	Yes (all types)

Thank You to Our Supporters in 2018

Celebrating
40
YEARS
1980-2020



The Kimberly and Eric J. Waldman
Department of Dermatology

Major Multiyear Gifts

Dow Family Charitable Fund
The Orentreich Family Foundation
Kimberly and Eric J. Waldman

\$200,000+

Mr. John Chr. M.A.M. Deuss
Mr. and Mrs. Robert S. Dow

\$20,000 to \$49,000

Mr. Thomas Kearns
Mr. and Mrs. Morris Mark
Dr. Rita C. O'Connor and
Mr. Theodore H. Schell
Huachen Wei, MD, PhD, and
Yang Wang, MD

\$10,000 to \$19,000

Susan V. Bershad Charitable Fund
Mr. Allan S. Gordon
Mrs. Janet C. Ross
Mr. and Mrs. Herbert M. Wachtell

\$5,000 to \$9,999

Mr. and Mrs. Lawrence D. Ackman
Douglas D. Altchek, MD
Mrs. Ay-Whang Hsia
Leon Kircik, MD
Robert and Sydelle Kleiman
Mr. Robert M. Schlein and
Ms. Emily Kroenlein
Walter P. Unger, MD

\$2,500 to \$4,999

Gary Goldenberg, MD, and
Kristina Goldenberg, MD
Mr. Harry S. Madoff
Mr. and Mrs. John H. Szalkay

\$1,000 to \$2,499

Alvin L. Adler, MD
Ms. Margaret A. Bancroft
Ms. Susan J. Berne and
Mr. Leonard Aconsky
Gary J. Brauner, MD
Mr. Peter Buchman
Robert Buka, MD, JD
Karen E. Burke, MD, PhD
The Dermatology Group, PC
Mrs. Rita R. Fleischmajer
Mr. and Mrs. Nelson Fleishman
David J. Goldberg, MD, JD
Norman Goldstein, MD
Charles A. Gropper, MD
Mr. Harvey A. Heffner
Bruce Heller, MD
Judith Hellman, MD
Esther Ho-Kung, MD
Mr. Elliott H. Jones
Bruce E. Katz, MD
Mr. and Mrs. Stanley Katz
Alan R. Kling, MD
Mr. Earle W. Kazis
Mrs. Susan Kornstein
Karen W. Landau, MD
Mr. Jerome Lauren
Eyal K. Levit, MD
Mr. and Mrs. Kevin M. Luzak
Ellen S. Marmur, MD
Mr. and Mrs. Mervin A. Matlin
Nelson Lee Novick, MD
Donald Rudikoff, MD
Allen N. Sapadin, MD, JD
Neal B. Schultz, MD

Eric S. Schweiger, MD
Lisa M. Silbret, MD, and
Alan L. Schechter, MD, PhD
James M. Spencer, MD
Mr. and Mrs. James Sprayregen
Mr. and Mrs. Stanford S. Warshawsky
Patricia S. Wexler, MD
Claire D. Wolinsky, MD, and
Eric Z. Berkowitz, MD
Ms. Evelyn Z. Zafran

\$500 to \$999

Jules S. Abadi, MD
Lisa E. Airan, MD
Arash Akhavan, MD
Mr. and Mrs. Merlin L. Alper
Gilberto Alvarez del Manzano, MD
Marcy Alvarez, DO
Dina N. Anderson, MD
Jason Applebaum, MD
Navin Arora, MD
Susan E. Binder, MD
Ellen Blank, MD
Robin R. Blum, MD
Anne Chapas, MD
David H. Ciocon, MD
Lily N. Clark, MD
Dr. and Mrs. David L. Cohen
Mrs. Maria C. Conder
Joyce C. Davis, MD
Adebola Dele-Michael, MD
Francis Dispaltro, MD
Mr. and Mrs. Harold Eicher
Mr. and Mrs. Robert Fabrikant
Jeremy S. Fenton, MD, and
Ms. Tracey J. Redmond
Cybele Fishman, MD
Steven J. Fishman, MD
Joshua L. Fox, MD
Francesca J. Fusco, MD
Cynthia M. Gerardi, MD

Gervaise L. Gerstner, MD
Elizabeth I. Goldberg, MD
Barry Goldman, MD
Mr. Harley J. Greenfield
Carin H. Gribetz, MD
Karen Hammerman, MD
Marie V. Hayag, MD
Cindy Hoffman, DO
Kenneth L. Howe, MD
Stephanie Hu, MD
Peter Ilowite, DO
Samer Jaber, MD
Jeannette Jakus, MD, MBA, and
Mr. Benjamin Kornfeind
Meryl J. Joerg, MD
Hirshel Kahn, MD
Mark D. Kaufmann, MD
Dmitry Khasak, MD
Dr. and Mrs. Hooman Khorasani
Charles C. Kleinberg, MD
Rebecca Kleinerman, MD
Mr. and Mrs. Robert D. Kroll
Jody A. Levine, MD, and
Elie Levine, MD
Robert Levine, MD
Emmanuel R. Loucas, MD
Lian Mack, MD
Mr. and Mrs. Mark S. Marinovich
Stephen E. Mercer, MD, PhD
Ms. Jean A. Morse
Adarsh V. Mudgil, MD
Charlotte Noorollah, DO
Kaleroy Papantoniou, MD
Carolyn T. Penrose, MD
Frederick A. Pereira, MD
Laurie J. Polis, MD
Ms. Ruth Porat and
Mr. Anthony Paduano
Morgan E. Rabach, MD

(continued on page 5)

PLEASE CONSIDER A TAX-DEDUCTIBLE CONTRIBUTION TO DERMATOLOGY RESEARCH AND EDUCATION

\$10,000
 \$5,000
 \$2,500
 \$1,000
 \$500
 \$100
 Other: \$

My gift is in honor of:

I have enclosed my check payable to:

The Mount Sinai Dermatology Fund



Give online to make your gift, please visit us at

<https://philanthropy.mountsinai.org/dermatology>

PLEASE FILL OUT BOTH SIDES

Please charge my gift to:

Visa American Express MasterCard

CARD NUMBER

EXPIRATION DATE

NAME ON CARD

SIGNATURE

Thank You to Our Supporters in 2018 *continued from page 4*

\$500 to \$999 (continued)

Jeffrey S. Roth, MD, PhD
Yulianna Russak, MD
Noah Scheinfeld, MD, JD
Hara J. Schwartz, MD and
Mr. Christopher E. Buck
Daniel W. Sherer, MD
Sherry Shieh, MD
Elizabeth C. Smith, MD
Dana K. Stern, MD
Jack P. Tom, MD
Susan L. Ungar, MD
Ms. Zenia R. Wand
Robert L. Warner, MD
Debra Wattenberg, MD
Mr. and Mrs. Eric C. Woglom

\$100 to \$499

Mr. Mehmet F. Acar
Alaleh Akhavan, MD
Ms. Susan Bard
Mr. Larry Barr
Ms. Gail V. Benjamin
Marcia Brody, MD
Mr. Daniel H. Burdick, II
Ms. Dierdre A. Burgman
James Briley, Jr., MD
Philip Bruder, MD
Ms. Kathleen Cafaro
Mr. and Mrs. Dan Carlinsky
Winifred Chu, DO, MPH
Russell W. Cohen, MD
Theodore Daly, MD
Nancy S. Dunetz, MD
Michele Farber, MD
Mr. Elias Feuer
Zoila D. Flashner, MD
Mr. and Mrs. Stephen G. Flax
Mr. and Mrs. Jimmy Franco
Brian Ginsberg, MD

Robyn Gmyrek, MD
Alison B. Gruen, MD
Ahmed S. Hadi, MD
Suhail M. Hadi, MBChB, FRCP
Scott Hammerman, MD
Miss Patti D. Kaplan
Mrs. Margot I. Karn
Bruce E. Katz, MD
Miriam Keltz Pomeranz MD
Mr. and Mrs. Alan Kersh
Mr. Frederick Kriegel
Mrs. Marilyn Kroop
Mr. and Mrs. Solomon Magid
Ms. Carolann F. Marshall
Mrs. Aurora Morgenstern
Ms. Judith Mose
Ms. Shirley A. Onacilla
Mr. and Mrs. J. Oppenheim
Barry N. Rosen, MD
Mr. David Saltonstall
Ms. Halle S. Schargel
Mr. Ronald Semaria
Ron M. Shelton, MD
Richard L. Torbeck, III, MD
Mrs. Naomi Wahrman
Mrs. Ellen M. Weinstein
Ms. Miwa Yokoyama
Jane Yoo, MD
Jordan Zuckerman, MD

Under \$100

Dr. Faina Baranov and
Mr. Vladimir Baranov
Ms. Eleanor G. Brennglass
Ms. Deborah Lee-Cheatam
Ms. Marsha A. Levi
Ms. Ruth A. Lewin
Mr. Richard J. Scollo
Mr. and Mrs. Donald Slater
Mr. and Mrs. Joseph W. Wallen

We apologize for any errors or omissions.



**FROM THE KIMBERLY AND ERIC J. WALDMAN
DEPARTMENT OF DERMATOLOGY**

Susan V. Bershad, MD
Editor

Yvonne B. Meyers
Managing Editor

Mark G. Lebwohl, MD
Waldman Chair of Dermatology
The Kimberly and Eric J. Waldman
Department of Dermatology
Professor of Dermatology
President, Editorial Board

Editorial Board
Brian J. Abittan, MD
Tomlee L. Abraham
Andrew F. Alexis, MD, MPH
Douglas D. Altchek, MD
Janet Nezhad Band
Gervaise L. Gerstner, MD
Noelani González, MD
Alan Kling, MD
Angela J. Lamb, MD
David S. Orentreich, MD
Jonathan P. Ungar, MD
Stephen Vance Wall
Patricia Wexler, MD
Vicky Kwan Wong
Mohammad-Ali Yazdani, MD

Design
Hallets Cove Studio

Our nameplate shows a normal skin surface under the microscope. Photo courtesy of Mark R. Wick, MD

Celebrating
40
YEARS
1980-2020



The Kimberly and Eric J. Waldman
Department of Dermatology

I'D LIKE NEWS AND INFORMATION FROM THE DEPARTMENT OF DERMATOLOGY AT MOUNT SINAI

Please add me/us to the mailing list of the Department of Dermatology

Please fill out both sides, detach this form and mail to:

The Kimberly and Eric J. Waldman Department of Dermatology
One Gustave L. Levy Place, Box 1047
New York, NY 10029-6574

Please contact us by telephone at 212-659-8500 or email your name and address to PhilanthropyOptOut@mountsinai.org if you wish to have your name removed from our distribution list of fundraising materials.

TITLE/NAME

ADDRESS

CITY/STATE/ZIP

E-MAIL ADDRESS

()

PHONE



**The Kimberly and Eric J. Waldman
Department of Dermatology**
One Gustave L. Levy Place, Box 1047
New York, NY 10029-6574

Non-Profit Org.
US Postage
PAID
Stamford, CT
Permit No. 195

Skin Health
SPRING/SUMMER 2019

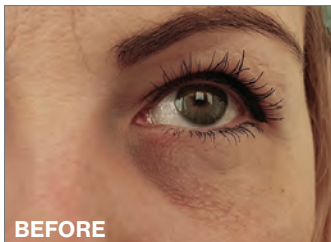


Say Goodbye to Under-Eye Circles

By Noelani González, MD, Director of Cosmetic Dermatology, Mount Sinai Doctors Ansonia

At one point or another, most of us have felt tired of looking tired: those under-eye circles just won't budge, no matter which eye cream or concealer we try. Discoloration and hollow grooves can sometimes be due to genetics but can also occur with aging. Beginning around the fourth decade, our faces gradually lose soft tissue, bone mass, and skin elasticity, causing sagging skin and shadows under our eyes.

How to counter-attack? Consider a tear-trough correction with a filler agent. A few injections of a hyaluronic acid filler can smooth out the under-eye furrows called tear troughs, which separate the lower eyelids from the cheeks. The best part is that you can see immediate improvement. Possible side effects include redness, swelling, and bruising for up to a week. Best results occur after about two weeks and slowly wear off after six months to two years.



The crease and hollow area below the eye show improvement after treatment with cosmetic filler injections.

F.Y.I. (For You Inside)
<ul style="list-style-type: none"> • The First Orentreich Professor: Anne Bowcock, PhD
<ul style="list-style-type: none"> • HPV Vaccination Update
<ul style="list-style-type: none"> • Mount Sinai Doctors Ansonia
<ul style="list-style-type: none"> • Thank You to 2018 Supporters
FIND OUR DOCTORS AT icahn.mssm.edu/dermdocs
BOOK AN APPOINTMENT
<p>To book a dermatology appointment at Mount Sinai Doctors Faculty Practice, please call 212-241-9728</p> <p>or to book online, please visit: www.MountSinaiDermatology.com</p>